Journal homepage: www.scienceletters.researchfloor.org

Journal of e-Science Letters

Original Research Article | ISSN 3041-5454

Impact of α-tocopherol on Kidney Functions of Male Rats Exposed to Deltamethrin

Amadi Azubuike Wowem, Eme Efioanwan Orlu, and Adetutu Olubunmi Obulor*

Department of Animal and Environmental Biology, Rivers State University, Nigeria

ABSTRACT

Deltamethrin is a widely used pyrethroid insecticide that can induce renal toxicity through oxidative stress, leading to structural and functional damage to the kidneys. α-tocopherol (Vitamin E), a potent antioxidant, may protect against deltamethrin-induced nephrotoxicity by scavenging free radicals and preserving renal tissue integrity. This study evaluated the protective efficacy of α-tocopherol against renal toxicity induced by deltamethrin exposure in adult male Wistar rats The experiment was conducted at the Animal House of the Department of Animal and Environmental Biology, Rivers State University, Port Harcourt, Nigeria. The study lasted for thirty-five (35) days. A total of forty male rats were selected into 8 groups (n=5). Group A was control, group B received deltamethrin 25 mg/kg bw/day only, C received deltamethrin only 12.5 mg/kg bw/day only, D received deltamethrin only 6.25 mg/kg bw/day only, E received 100mg/kg/bw/day α-tocopherol only, F received 100mg/kg/bw/day α-tocopherol + 25 mg/kg bw/day deltamethrin, G received 100mg/kg/bw/day α-tocopherol + 12.5 mg/kg bw/day deltamethrin and H received 100mg/kg/bw/day α-tocopherol + 6.25 mg/kg bw/day deltamethrin. At the end of the treatment period, blood samples were collected for analysis. Total protein was analyzed using the spectrophotometric method of biuret, Bradford and erythrosine – b, albumin was estimated, creatinine and urea was done using enzymatic method. Histological sections of the kidney were mounted on slides, stained with hematoxylin and eosin (H&E). Photomicrographs were generated. Results show a dose-dependent significant (p=0.05) increase in Albumin, Urea, Total protein and creatiine level in groups B,C,D compared to other groups co administered α-tocopherol. Histopathological examination of deltamethrin-only groups revealed marked glomerular distortion, tubular cast formation, and epithelial deformation driven by severe oxidative stress. In contrast, co-treatment with α-tocopherol preserved renal architecture, maintaining intact glomeruli and preventing tubular necrosis. In conclusion deltamethrin induces dose-dependent nephrotoxicity while α-tocopherol confers substantial protection against these adverse effects suggesting that α-tocopherol may serve as a beneficial therapeutic agent in attenuating pesticide-induced renal injury.

Keywords: *α-tocopherol, antioxidant, biomarkers, deltamethrin, histology, Kidneys, nephrotoxicity.*

Introduction

The global human population is projected to surpass 9.7 billion by 2050 [1] . The swift increase in population has necessitated heightened agricultural output to guarantee food security and mitigate the risk of widespread malnutrition [2]. Pesticides, whether chemical or biological, are compounds intentionally formulated to exterminate, deter, or otherwise manage pests that jeopardize crops, livestock, human health, or the environment.

Citation: Amadi Azubuike Wowem, Eme Efioanwan Orlu, and Adetutu Olubunmi Obulor (2026). Impact of α-tocopherol on Kidney Functions of Male Rats Exposed to Deltamethrin. *Journal of e-Science Letters.*
DOI: https://doi.org/10.51470/eSL.2026.7.3.07

Received: 07 April 2026
Revised: 09 May 2026
Accepted: 06 June 2026
Available: July 13 2026

Corresponding Authors: **Adetutu Olubunmi Obulor**
Email: **godwin.obulor1@ust.edu.ng**

© 2026 by the authors. The license of Journal of e-Science Letters. This article is an open access article distributed under the terms and conditions of the Creative Commons Attribution (CC BY) license (https://creativecommons.org/licenses/by/4.0/)

Today, they are indispensable to contemporary agriculture. In their absence, global agricultural output would significantly decline, with estimates indicating that pesticides mitigate losses amounting to approximately 30–40% of potential worldwide production [3]. This protection results in billions of dollars saved annually by preserving crops from insects, weeds, fungi, and other pests that would otherwise ruin food supplies [3,4]. The global pesticide market has expanded considerably over recent decades, reflecting agriculture's growing dependence on pesticides for effective pest management and crop protection.

Pesticides have a crucial role not just in agriculture but also in public health initiatives. Vector control insecticides are employed to combat mosquitoes, the primary vectors of malaria, dengue fever, Zika virus, and other arboviral illnesses. Consequently, public health vector management in tropical and subtropical regions, where vector-borne diseases result in significant morbidity and mortality, mostly relies on the application of pesticides [5]. The extensive usage of pesticides has generated significant concern due to their potential adverse effects on non-target creatures. These non-targets may include beneficial insects, aquatic species, wildlife, domestic animals, and humans [3]. Pesticides permeate the soil, water, and air, thereby promoting biodiversity decline, disrupting food web dynamics, and jeopardizing non-target species, including pollinators and aquatic organisms [6].

Long-term exposure, especially among agricultural workers, has consistently been associated with an increased risk of cancer (notably non-Hodgkin lymphoma), neurological disorders (such as Parkinson's disease), endocrine disruption, and respiratory issues. The idea of selecting a toxicant that only targets pests without injuring or impacting other organisms has yet to be achieved.

Pyrethroid insecticides are one of the most extensively employed categories of synthetic pesticides worldwide. They were initially marketed commercially in the 1970s. Currently, they constitute a significant portion of the global insecticide market, utilized in agricultural, mosquito control initiatives, veterinary goods, and domestic pest management [7]. While pyrethroids are generally considered safe for mammals, experimental studies indicate that even minimal exposure can lead to detrimental effects on the nervous system, liver, kidneys, and other organs, with severe consequences arising from higher doses [7,8].

Nephrotoxicity induced by xenobiotics, including pesticides like deltamethrin, is a significant clinical and public health issue. Toxic renal injury may present as acute kidney injury (AKI), and with ongoing or recurrent exposure, it can result in chronic kidney disease with irreversible functional loss [9]. The mechanism of kidney toxicity induced by the toxicant are intricate and encompass direct tubular cell damage via oxidative stress and mitochondrial dysfunction, intratubular obstruction, alterations in renal hemodynamics, immune-mediated injury, as well as inflammatory and apoptotic signaling pathways [10].

The extensive application of deltamethrin in agricultural and domestic pest management has generated considerable apprehension regarding its possible detrimental impacts on kidney health, especially through pathways related to oxidative stress and nephrotoxicity [7, 11]. Extended exposure to this pyrethroid pesticide has been linked to biochemical and structural changes in essential organs, consequently heightening the risk of renal impairment. Alpha-tocopherol is a potent antioxidant that significantly improves immune function and supports vascular health [12,13]. Despite increasing awareness of pesticide-induced organ toxicity, there is a scarcity of experimental investigations examining effective preventative measures that can alleviate renal damage from such chemical exposures. Moreover, the nephroprotective and antioxidant properties of alpha-tocopherol in mitigating deltamethrin-induced renal damage remain inadequately investigated and defined. The absence of comprehensive data results in a significant knowledge gap, requiring systematic research into the preventive effectiveness of alpha-tocopherol against deltamethrin-induced oxidative damage and renal functional impairment.

Methodology

Study location

The experiment was conducted at the Animal House of the Department of Animal and Environmental Biology, Rivers State University, Port Harcourt, Nigeria. GPS $4^0$48 14"N 6^0 59' 12"

Animal care and management

Forty sexually mature male Wistar rats, with a mean body weight of weight 180.13 ± 2.05g were obtained from the Department ofAnimal and Environmental Biology, Rivers State University Port Harcourt, Nigeria. The animals were housed individually in clean plastic cages under standard laboratory conditions, including a 12-hour light and 12-hour dark photoperiod, ambient temperature of 26 ± 2°C, and relative humidity of approximately 54%. The rats were allowed a two-weeks acclimatization period before the commencement of the experiment. During this period, they were fed standard rodent pellets and provided with clean drinking water *ad libitum.* All experimental procedures were conducted in strict compliance with institutional animal care and use protocols and adhered to internationally accepted guidelines for the ethical treatment of experimental animals.

Study Design

A total of forty (40) male Wistar rats (mean weight 180.13 ± 2.05g) were randomly divided into eight groups (n=5). Group A was the control, group B received deltamethrin 25 mg/kg bw/day only, C received deltamethrin only 12.5 mg/kg bw/day only, D received deltamethrin only 6.25 mg/kg bw/day only, E received 100mg/kg/bw/day α-tocopherol only, F received 100mg/kg/bw/day α-tocopherol + 25 mg/kg bw/day deltamethrin, G received 100mg/kg/bw/day α-tocopherol + 12.5 mg/kg bw/day deltamethrin and H received 100mg/kg/bw/day α-tocopherol + 6.25 mg/kg bw/day deltamethrin. The deltamethrin doses provided (25 mg/kg, 12.5 mg/kg, and 6.25 mg/kg body weight) were determined from toxicological investigations by [14].

Biochemical biomarkers analysis of kidney

Blood samples were collected individually by cardiac puncture into sterile tubes and the serum separated at 2500rpm for 10min and stored for further analysis. Total protein was analyzed using the spectrophotometric method of biuret, Bradford and erythrosine – b,creatinine and urea was done using enzymatic method [15]. Total bilurubin (TB), Albumin (ALB), Creatinine were assayed according to Sigma Diagnostics based on standard procedures [16,17]

Histopathological evaluation of the kidney

Known weight of the kidney was fixed in Bouin's fixative and processed according to the protocol described by [18] sectioned with a Digital Microtome Model A O Spencer No. 820 at 5um thick and stained with Hematoxylin and Eosin (H &E) Photomicrographs were generated with a digital Microscope Biosphere Miller B with an image processor DN2 – Microscopy Image processing Software at X400 magnification.

RESULTS

Effect of α-tocopherol on kidney biomarkers of male rats exposed to deltamethrin

Fig 3.1 shows the mean serum albumin (ALB) levels of male rats exposed to α-tocopherol and deltamethrin. These values varied significantly across the experimental groups, as shown by the Tukey HSD post-hoc analysis. Group A recorded 26.3 ± 2.07g/dL while Groups B, C, and D were 36.9 ± 3.3g/dL, 33.2 ± 3.99g/dL and 33.1 ± 1.85g/dL respectively which had the highest mean values when compared to the control respectively. These values did not differ significantly from one another ($p > 0.05$). In contrast, Group E exhibited the lowest mean value of 17.6 ± 0.6g/dL when compared with the control. Groups F, G and H showed mean values of 25.0 ± 3.18g/dL, 20.6 ± 1.6g/dL, 20.5 ± 1.91g/dL significantly different from the control respectively. The observed differences confirm a statistically significant effect of treatment on serum albumin levels among the groups.Mean total protein levels differed significantly among the experimental groups. (Fig 3.2). Group A recorded a mean value of 54.4±3.86g/dL.

Groups B, C and D showed the highest mean values of 68.6±1.82g/dL, 66.2±1.79g/dL and 61.4±2.51g/dL respectively when compared to the control. In contrast, Group E exhibited the lowest mean total protein level that was 47.3±4.04g/dL significantly ($p < 0.05$) different from control. Group A displayed a moderately reduced total protein level, which was significantly lower than Groups B, C, and D but comparable to groups with shared lettering. Groups F, G, and H showed intermediate total protein values of 62.5±1.20g/dL, 60.4±2.91g/dL, 57.2±3.16g/dL significantly different from control respectively. However, these findings indicate a significant treatment-related variation in total protein levels across the groups ($p < 0.05$).Fig 3.3 shows mean serum urea concentrations which also varied significantly among the experimental groups. Group A showed the lowest mean urea level of 3.4±0.4mg/dL and differed significantly from all groups with higher urea values ($p < 0.05$). Groups B, C, D, and F recorded the highest mean values of (5.5±0.3mg/dL; 5.43±0.416mg/dL, 5.33±0.2mg/dL, 5.63±0.3mg/dL) that significantly differed from the control but did not differ significantly from one another ($p > 0.05$). Group E exhibited a moderately elevated urea concentration of 4.97±0.6mg/dL higher than the control, which was comparable to the high-urea groups but significantly ($p < 0.05$) (3.41±0.44mg/dL) In contrast, Groups G and H displayed 4.23±0.2mg/dL, 4.07±0.2mg/dL intermediate urea concentrations that were higher than control and were not significantly different from each other but were significantly lower than Groups B, C, D, and F ($p < 0.05$). However, the results demonstrate a significant effect of treatment on serum urea levels across the experimental groups ($p < 0.05$).Mean Serum creatinine levels showed significant variation across the experimental groups. Group A displayed a mean value of 46.6±1.47mg/dL which was a relatively low creatinine level, but higher than Group E(41.1±0.70mg/dL) which was the lowest. (fig 3.4). Groups B, C, D and F recorded the higher mean creatinine concentration of 60.4±1.05mg/dL, 58.9±1.22mg/dL, 53.6±3.08mg/dL and 59.7±1,76mg/dL higher than the control and did not differ significantly ($p > 0.05$) from each other. Groups E and H demonstrated, 41.1±0.71mg/dL and 49.1±3.33mg/dL intermediate creatinine values higher than the control and did not differ significantly from one another or from selected higher groups.

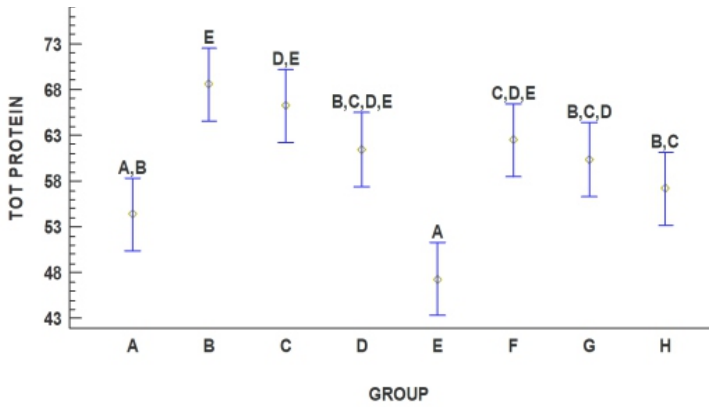

Fig 3.1: Effect of α-tocopherol on Tot. Protein levels levels in male rats exposed to deltamethrin

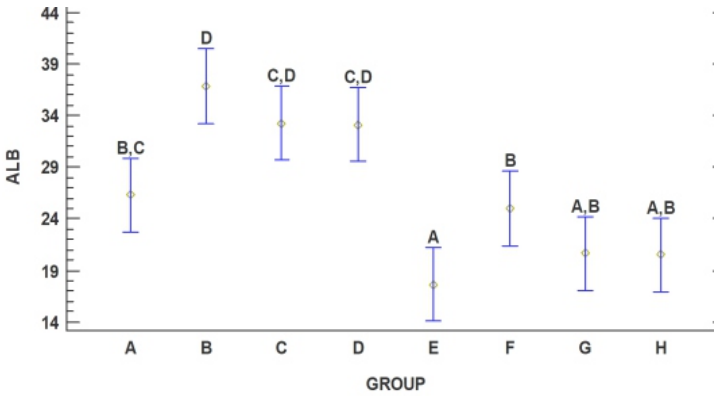

Fig 3.2: Effect of α-tocopherol on Albumin (ALB) in male rats exposed to deltamethrin

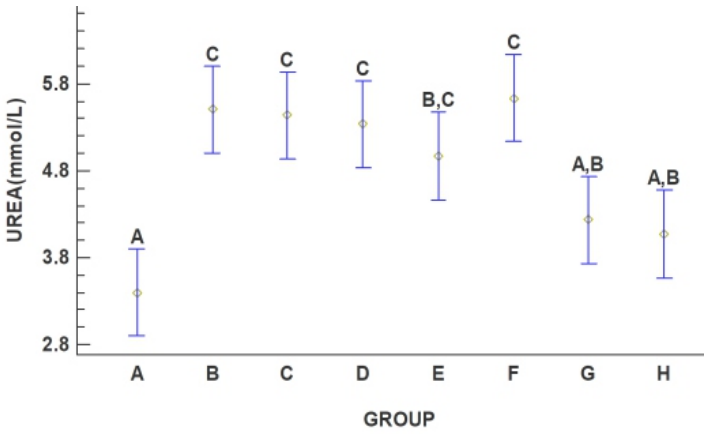

Fig 3.3: Effect of α-tocopherol on serum urea levels creatinine levels in male rats exposed to deltamethrin

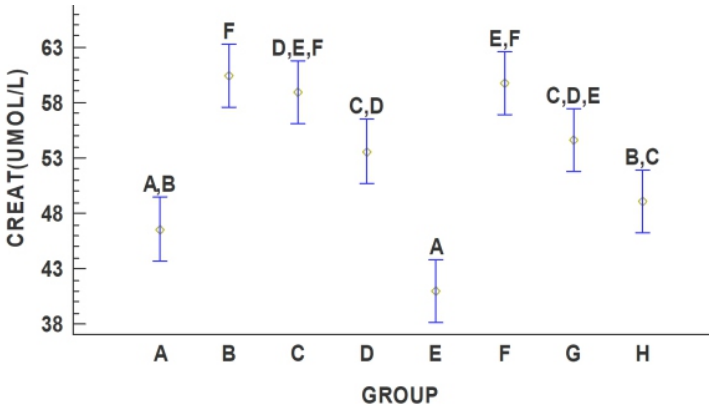

Fig 3.4: Effect of α-tocopherol on in male rats exposed to deltamethrin

Kidney Histology

Fig 3.5 is the photomicrograph in group A. The renal tubules are well organized with clearly defined lumina. Tubular epithelial cells are intact, closely packed, and uniformly arranged. In fig 3.6, Renal tubules appear distorted, with loss of normal epithelial arrangement. Numerous tubular epithelial cells show pronounced nuclear alterations. The presence of tubular casts (C) within the lumen and widening of interstitial spaces. In Fig. 3.7 glomerulus appears distorted; surrounding renal tubules show loss of normal epithelial arrangement. Lumina are irregular and narrowed; nuclei appear darkly stained and condensed, consistent with nuclear degeneration (pyknosis); expansion of the interstitial cells is evident.

Fig 3.8 is the kidney tissue in group D with mild, early renal alterations. The glomerulus shows an increase in cellularity. Some tubular cells show mild cytoplasmic swelling, but there is no obvious necrosis or cast formation. Most nuclei appear slightly darker, suggesting early nuclear stress. Fig 3.9 is renal tissue exposed to α-tocopherol only. The glomerulus appears well defined and intact, with normal cellularity and a clearly demarcated Bowman's space. Distal tubules (DT) show normal epithelial lining with preserved cell arrangement and patent lumina. Tubular epithelial cell nuclei are round to oval and evenly stained, indicating healthy, viable renal cells. Tubules maintain their normal architecture without dilation. The interstitium appears compact and free from inflammatory infiltrates. Fig. 3.10 is the renal tissue of animals treated with 25 mg/kg deltamethrin + α-tocopherol. Although some lesions remain, the overall renal architecture is notably improved compared with animals exposed to 25 mg/kg deltamethrin alone. The labeled "C" areas show tubular casts, which consist of sloughed epithelial cells and proteinaceous material within the tubular lumen. The tubules show partial restoration of epithelial lining, though some cells still exhibit mild degeneration and disorganization. In fig 3.11, the interstitium appears compact, with no obvious inflammatory infiltrates. Improved tubular epithelial integrity, reduced nuclear abnormalities, Near-normal renal architecture is evident. In fig 3.12, Proximal tubules (PT) appear intact, with preserved epithelial lining. Distal tubules (DT) are well organized, with normal cellular arrangement and clear luminal spaces, indicating preserved tubular function. The glomerulus (G) shows normal cellularity and an intact Bowman's capsule, Absence of tubular inflammatory infiltrates, and normal nuclear morphology of tubular epithelial cells.

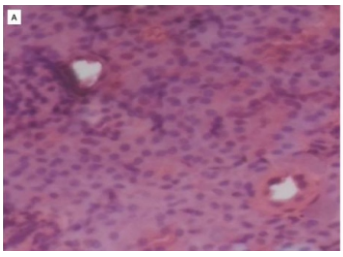

Fig 3.5: Photomicrograph of kidney tissues in group A @X40 Necrotic cell, C: casts

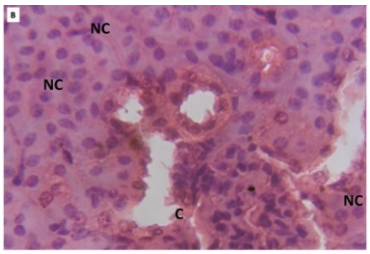

Fig 3.6: Photomicrograph of kidney tissues in group B @X40

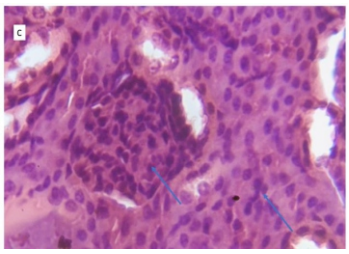

Fig 3.7: Photomicrograph of kidney tissues in group C @X40

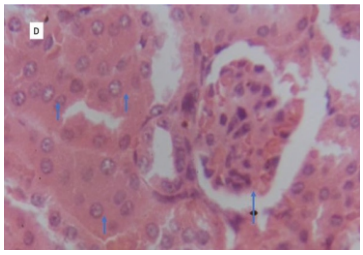

Fig 3.8: Photomicrograph of kidney tissues in group D @X40

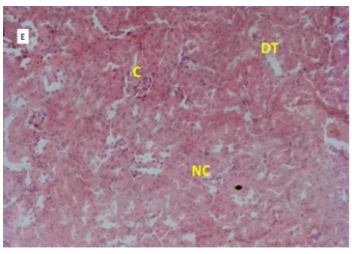

Fig 3.9: Photomicrograph of kidney tissues in group E @X40C: casts NC: Necrotic cell.

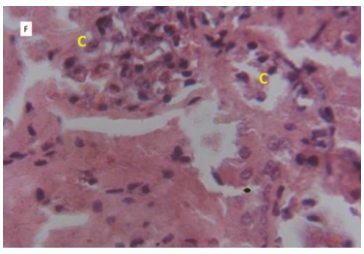

Fig 3.10: Photomicrograph of kidney tissues in group F @X40 C: casts

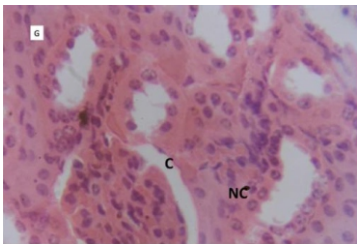

Fig 3.11: Photomicrograph of kidney tissues in group G @X40 NC: Necrotic cell, C: casts

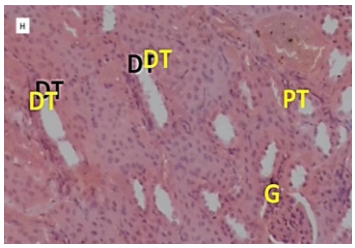

Fig 3.12: Photomicrograph of kidney tissues in group H @X40 DT: Distal tubule, PT: Proximal tubule, G: glomerulus

DISCUSSION

Biochemical parameters measured in serum, such as albumin, total protein, urea and creatinine, are sensitive measures of renal functional state with greater application in the detection of toxicological effects of xenobiotics, such as this class of pyrethroids and more specifically deltamethrin. An increase in albumin is an indication of damaged kidney filters causing glomerular damage. However, an increase in protein level is a common indicator of renal injury. An increase in the urea level is commonly associated with tubular necrosis, whereas a raised creatinine level is characteristic of extensive damage to the glomeruli alongside infiltration of inflammatory cells into the interstitium.

The significantly increased serum ALB levels in Groups B, C, and D (deltamethrin-only groups) compared to Control Group A could be an early indicator for the start of a kidney compensatory process in the presence of deltamethrin. ALB is only synthesized in the liver; thus, changes in ALB concentrations are generally associated with modified renal protein synthesis and/or plasma volume [9,10,18]. The significantly decreased level of ALB in Group E (α-tocopherol), the only group that was administered vitamin E, may be attributable to a reduction in albumin synthesis or plasma protein effects; however, the level was in a different significant grouping. Moderate ALB levels in Groups F, G, H (deltamethrin and vitamin E) may be indicative of a lesser degree of deltamethrin hepatotoxicity and may suggest a protective effect by the administration of vitamin E. In addition, total protein concentrations were observed to be significantly different between all groups, again indicative of renal pathology. Elevated total protein in groups B, C and D of deltamethrin-only fed groups, (2.2±0.15, 2.3±0.08, 2.09±0.11g/l, respectively), could be indicative of an increased synthesis of acute-phase proteins following oxidative stress and tissue damage caused by deltamethrin intoxication. In contrast, the significantly depleted concentrations of total protein found in Group E, (1.46±0.02g/l), supported evidence of the speculated effect of vitamin E alone on protein metabolism, where direct effects on renal function are conceivable. However, in the groups fed both deltamethrin and alpha-tocopherol (Groups F, G and H), (2.13±0.01, 1.97±0.02 and 2.13±0.05g/l, respectively), intermediate concentrations of total protein indicate that alpha-tocopherol supplementation assisted in preventing the effects of deltamethrin intoxication on protein biosynthesis, likely through antioxidant effects on the hepatocyte [19].

Serum urea concentrations were used as a biological indicator of the functional capacity of the kidney. The significant urea concentrations recorded in groups B, C, D, and F are an indication of the increased rate of protein degradation and/or reduced renal elimination capacity caused by deltamethrin.

The synthetic pyrethroids, including deltamethrin, have been shown to elicit nephrotoxic effects via the generation of oxidative stress, which causes lipid peroxidation, cell damage, and death within renal tubules, as well as reduction of both glomerular filtration rate and reabsorption in the tubules. The serum urea concentrations in group A, being significantly lower than those of the experimental groups, are an indication of neither altered renal function, with respect to urea time of removal or rate of degradation. The serum urea concentrations of group G and H are comparable to group A, and this can be attributed to the presence of vitamin E. The role of vitamin E in protecting against the potential intoxication effects of cypermethrin is not confirmed, as vitamin E supplementation did not significantly reduce serum urea concentrations at the higher deltamethrin dose (E). The serum urea concentrations in group E are considerably lower than those in the high-dose deltamethrin groups (C and D), and this has to be put down to the fact that vitamin E did not display any toxicity alone.

Moreover, serum creatinine further supported the renal changes in this experiment. Groups B, C, and F had higher serum creatinine levels, implying a reduction in the glomerular filtration rate as a result of renal ischemia in deltamethrin-treated animals. Creatinine is a sensitive marker of renal disease, and its accumulation in serum is due to defective glomerular function [20,21]. The marked reduction in serum creatinine in groups E and control shows that renal function was intact, while the suppressed serum creatinine levels in G and H may imply a dose-dependent protective function by vitamin E in the kidney against lipid peroxidation in renal tissues and maintain nephron restoration [18, 22].

This observation is consistent with several previous reports which have demonstrated the protective activities of antioxidants against pesticide-induced oxidative stress and organ toxicity [11,18, 20]. [22] demonstrated the protective effect of vitamin E in attenuating deltamethrin-induced nephrotoxicity by maintaining the renal histoarchitecture and serum urea and creatinine levels towards normal values. [23] Also observed significant amelioration of parameters of liver and kidney function after vitamin E co-administration in pesticide-treated animals. Moreover, Vit C supplement administration for 35 days caused a significant difference in kidney parameters, regeneration of Nephrons, and reduction in kidney tissue inflammation, indicating the efficacy of Vit C supplement over Costus afer [11].

Acknowledgements

The following individuals are acknowledged for their contributions: Dr Wekhe Aruchi for his assistance with the experimental animals; Mr Uche and Abbey for the biochemical and histopathological analysis. Mr Nnodim Lasbry for carrying out the statistical analysis.

References

1. Hamad, A. (2025). Food 2050 concept: The trends that shape the future of our food systems. *Journal of Agriculture and Food Research*, 20, 101416. https://doi.org/10.1016/j.jafr.2025.101416
2. Aiyedogbon, J. O., Anyanwu, S. O., Isa, G. H., Petrushenko, Y., & Zhuravka, O. (2022). Population growth and food security: Evidence from Nigeria. *Problems and Perspectives in Management, 20*(2), 402–410. https://doi.org/10.21511/ppm.20(2).2022.33.
3. Sharma, A., Kumar, V., Shahzad, B., Tanveer, M., Sidhu, G. P. S., Handa, N., Kohli, S. K., Yadav, P., Bali, A. S., Parihar, R. D., Dar, O. I., Singh, K., Jasrotia, S., Bakshi, P., Ramakrishnan, M., Kumar, S., Bhardwaj, R., & Thukral, A. K. (2019). Worldwide pesticide usage and its impacts on ecosystems. *SN Applied Sciences, 1*, Article 1446. https://doi.org/10.1007/s42452-019-1485-1
4. De Groote, H. (2022). Economic analysis of pest problems in agriculture and food chains in Africa. *Current Opinion in Insect Science, 54*, 100969. https://doi.org/10.1016/j.cois.2022.100969
5. World Health Organization. (2022). *Global vector control response 2017–2030: Progress report 2021*. World Health Organization. https://www.who.int/publications/i/item/9789240054887.
6. Pathak, V. M., Verma, V. K., Rawat, K. P., Kaur, B., Babu, N. R., Sharma, A., ... & Singh, J. (2022). Current status of pesticide effects on environment, human health and it's eco-friendly management as bioremediation: A comprehensive review. *International Journal of Environmental Research and Public Health*, 19(5), 2833.
7. Kaczyński, P., Łozowicka, B., & Wołejko, E. (2023). *Pyrethrins and pyrethroids: A comprehensive review of natural occurring compounds and their synthetic derivatives. Plants, 12*(23), 4022. https://doi.org/10.3390/plants12234022.
8. Chrustek, A., Hołyńska-Iwan, I., Dziembowska, I., Bogusiewicz, J., Wróblewski, M., Cwynar, A., & Olszewska-Słonina, D. (2018). *Current research on the safety of pyrethroids used as insecticides*. Medicina, 54(4), 61. https://doi.org/10.3390/medicina54040061.
9. Perazella, M. A., & Rosner, M. H. (2022). Drug-induced acute kidney injury. Clinical Journal of the American Society of Nephrology, 17(8), 1220–1233.
10. Vaidya, V. S., Ferguson, M. A., & Bonventre, J. V. (2008). Biomarkers of acute kidney injury. Annual Review of Pharmacology and Toxicology, 48(1), 463–493. https://doi.org/10.1146/annurev.pharmtox.48.113006.094615.
11. Orlu, E. E., Obulor, A. O., Wekhe-Emenike, A. & Orlu, R.C. (2025). "Comparative Evaluation of the Potential Antioxidant Activity of Costus Afer Aqueous Stem Extract and Vitamin C Supplement on Liver of Male Swiss Mice Subjected to Sub-Chronic Exposure of Dichlorvos". Annual Research & Review in Biology 40 (9):97-103. https://doi.org/10.9734/arrb/2025/v40i92308.
12. Traber, M. G., & Head, B. (2021). *Vitamin E: How much is enough, too much and why! Free Radical Biology and Medicine, 177*, 212–225. https://doi.org/10.1016/j.freeradbiomed.2021.10.028.
13. Garg, A., & Lee, J. C.-Y. (2022). *Vitamin E: Where are we now in vascular diseases? Life, 12*(2), 310. https://doi.org/10.3390/life12020310.
14. Ichimura, T., Hung, C. C., Yang, S.A., Stevens, J.L., Bonventre, J.V. (2004). Kidney injury molecule- 1. A tissue and urinary biomarker for nephrotoxicant-induced renal injury.Am J Physiol Renal Physiol. 286:F552–63.
15. Lowry, O.H., Rosebrough, N.J., Farr, A.L. & Randall, R. J. (1951) Total protein estimation by Lowry's method. Journal of Biology and Chemistry. 193:265.
16. Doumas, B.T., Watson, W.A. & Biggs, H.G.(1971). Albumin standards and measurement of serum-albumin with bromocresol green. Clinical ChimicaActa Journal. 31:87- 92.
17. Orlu, E. E., & Obulor, A. O. (2021). Protective role of different local spices on lambda-cyhalothrin-induced nephrotoxicity in male mice. Asian Journal of Biology, 13(4), 61–70. https://doi.org/10.9734/ajob/2021/v13i4301.
18. Obulor, A. O., Aruchi, W. E., Mpakaboari, R. S., Izeoma, N. S., & Orlu, E. E. (2024). Effects of aqueous extracts of *Costus afer* and Vitamin C supplement on renal damage in male mice subjected to subchronic exposure of Dichlorvos. *Journal of Applied Life Sciences International, 27*(6), 10-16. https://doi.org/10.9734/jalsi/2024/v27i6661.

19. Wekhe-Emenike, A., Obulor, A.O. & Orlu, E.E. (2025). Time-Dependent Alterations in Renal Biomarkers of Mice Exposed to Aspartame and Ethanolic Extract of Sacoglottis gabonensis. *Asian Journal of Advances in Research* 8 (1):538-46. https://doi.org/10.56557/ajoair/2025/v8i1547.
20. Soudani, N., Troudi, A., Bouaziz, H., Ben Amara, I., &Zeghal, N. (2010). Ameliorative effects of vitamin E on deltamethrin-induced oxidative stress in rat kidney. *Toxicology and Industrial Health, 26*(10), 635–643. https://doi.org/10.1177/0748233710375692.
21. El-Gendy, K. S., Aly, N. M., Mahmoud, F. H., Kenawy, A., & El-Sebae, A. K. (2010). The role of vitamin E in protecting against cypermethrin-induced oxidative stress in rat liver and kidney. *Journal of Environmental Science and Health, Part B, 45*(5), 442–450. https://doi.org/10.1080/03601231003799898.